




## Orolabial Melanosis: Principles of Formulating a Clinical Diagnosis

Hojammet Jumayev<sup>1</sup>, Aybolek Tachmukammedova<sup>2</sup>, Begench Serdarov<sup>1</sup>, Garabeg Goshayev<sup>3\*</sup>, Batyr Allagulyyev<sup>4</sup>, Aman Geldiyev<sup>5</sup>

Received: 17 Jun 2025

Accepted: 29 Nov 2025

Published: 13 Jan 2026

### Abstract

**Background:** The group of melanotic lesions (ML) of the orolabial region is extremely diverse, creating objective difficulties in differential diagnosis. To perform a comprehensive differential diagnostic evaluation and to plan treatment strategies, it is advisable to supplement the clinical classification of ML with objective diagnostic criteria.

**Methods:** This retrospective, single-center study was designed according to the principles of clinical examination, including objective examination of the oral cavity, periodontal tissue assessment with evaluation of the Greene-Vermillion hygiene index, periodontal indices (papillomarginal-alveolar - PMA, SPITN), and assessment of the location, size, and staining intensity of ML using the authors' method, followed by statistical analysis. Conservative treatment of diseases of the oral mucosa and periodontium with subsequent dynamic observation was carried out for periods of 3 to 10 years. Statistical processing of the clinical data was performed using Microsoft Excel and the Statistica package, including calculation of the mean and standard error, Student's t-test, and analysis of variance with subsequent pairwise comparisons to determine the probability of error (p). Differences between means were considered statistically significant at  $P < 0.05$ .

**Results:** A total of 318 cases of ML in the orolabial region were examined. The size of ML foci was found to increase significantly with the depth and extent of the inflammatory process in the periodontium. Depending on the disease form, the average length of lesions increased more markedly ( $P < 0.01$ ) than the average width ( $P < 0.05$ ). According to the authors' method for objective assessment of ML staining intensity in the oral mucosa and lips, comparison of staining intensity with the nosological forms of inflammatory periodontal diseases showed the following patient distribution: degree I in 82 patients (25.8%), degree II in 164 patients (51.6%), and degree III in 72 patients (22.6%). Statistically significant differences for ML degree I were identified between the first and second nosological forms of inflammatory periodontal diseases ( $P < 0.05$ ). For ML degree II, significant differences were observed between the first and second, first and third, first and fourth, second and third, and second and fourth nosological forms ( $p < 0.05$ ). Analysis of ML degree III also demonstrated a high level of statistically significant differences between the second and third, and second and fourth nosological forms ( $P < 0.01$ ). For objective assessment of ML, clinical classification criteria and diagnostic principles were developed that reflect the characteristics of their course depending on the hygienic status of the oral cavity and periodontal tissues.

**Conclusion:** Unification of fundamental approaches to formulating a clinical diagnosis allows for differential diagnosis of ML, planning of treatment and preventive measures, and assessment of disease dynamics using objective criteria.

**Keywords:** Melanotic Lesions, Mucous Membrane, Periodontium, Clinical Diagnosis

\*This work has been published under CC BY-NC-SA 4.0 license.

Copyright© Iran University of Medical Sciences

**Cite this article as:** Jumayev H, Tachmukammedova A, Serdarov B, Goshayev G, Allagulyyev B, Geldiyev A. Orolabial Melanosis: Principles of Formulating a Clinical Diagnosis. *Med J Islam Repub Iran.* 2026 (13 Jan);40:5. <https://doi.org/10.47176/mjiri.40.5>

**Corresponding author:** Dr Garabeg Goshayev, [garabeg@gmail.com](mailto:garabeg@gmail.com)

1. Department of Postgraduate Training in Dentistry, Myrat Garryyev State Medical University of Turkmenistan, Ashgabat, Turkmenistan
2. Myrat Garryyev State Medical University of Turkmenistan, Ashgabat, Turkmenistan
3. Department of Science, Myrat Garryyev State Medical University of Turkmenistan, Ashgabat, Turkmenistan
4. Department of Orthopedic and Surgical Dentistry, Myrat Garryyev State Medical University of Turkmenistan, Ashgabat, Turkmenistan
5. Research-diagnostic Laboratory of Pathomorphology of the International Educational and Scientific Center of the Ministry of Health and Medical Industry of Turkmenistan, Ashgabat, Turkmenistan

### ↑What is “already known” in this topic:

In the 3rd edition of the International Classification of Diseases for Oncology (ICD-O), within the section on diseases of the oral mucosa (OM), tumors originating from the melanogenic system include lentiginous melanoma, pigmented nevi, and non-pigmented nevi. Moreover, the proposed clinical classifications of melanotic lesions of the oral mucosa and lips are based solely on etiopathogenetic mechanisms.

### →What this article adds:

The results of the study allowed us to develop a clinical classification of melanotic lesions (ML) of the oral mucosa and lips, the occurrence of which is not associated with racial pigmentation, somatic diseases, or exogenous factors. Based on this classification, principles for formulating a clinical diagnosis were developed, enabling a comprehensive and objective presentation of the clinical picture, facilitating differential diagnosis, and improving treatment effectiveness for ML.

## Introduction

In modern scientific literature, the term “melanotic lesions” (ML) of the orolabial region encompasses pigmentation of the oral mucosa and lips that is pathogenetically associated with increased functional activity of mucosal melanocytes (MM), either alone or in combination with melanocyte proliferation (1-5). According to numerous studies, the development of ML of the oral mucosa and lips may be triggered by both endogenous and exogenous factors and conditions (3, 6-12). Various authors report that patient gender and age, as well as the size, location, and color of ML, vary widely, ranging from a “coffee with milk” shade to dark brown and black (1-3, 6-8, 13).

It is noteworthy that in the 3rd edition of the International Classification of Diseases for Oncology (ICD-O), within the section on diseases of the oral mucosa, only pigmented and non-pigmented nevi, as well as lentiginous melanoma of the oral mucosa, are classified as tumors originating from the melanogenic system (14). The absence of other nosological forms in the classification is probably due to the fact that, despite fairly extensive studies on the clinical and morphological features of ML in the orolabial region, no consensus has been reached regarding their clinical and morphological classification. As a result, a variety of terms are used in the scientific literature to designate ML, including “melanotic spot,” “melanosis,” “melanoacanthoma,” “melanopathy,” and “melanoplakia” (3, 5-8, 10, 15).

However, most proposed clinical classifications of melanotic lesions of the oral mucosa and lips are based solely on etiopathogenetic mechanisms. Scientific publications of the last decade lack information on the periodontal status in this category of patients, and the description of the shade and intensity of periodontal pigmentation remains a largely subjective criterion.

In view of the above, to perform comprehensive differential diagnostic measures, plan further treatment strategies, and monitor treatment effectiveness, it is advisable to supplement the clinical classification of ML of the orolabial region with objective diagnostic criteria.

## Methods

Clinical and statistical research methods were used in the study. The study design was a retrospective, single-center clinical trial with subsequent statistical processing of the obtained data.

The following criteria were used for patient selection: presence of ML in the oral cavity and lips; absence of signs of racial pigmentation; no history of oral medication use that could contribute to the development of ML (e.g., antimalarial drugs, certain anticancer agents, contraceptives, etc.); absence of somatic diseases, including endocrine, hereditary, infectious, and oncological conditions; uncomplicated allergic history; absence of bad habits.

Conservative treatment of identified inflammatory diseases of the oral mucosa and periodontium, followed by dynamic observation, was carried out over periods ranging from 3–10 years.

Written informed consent was obtained from each patient prior to participation in the study (Decision of the Ethics

Committee No. 1665, dated 10/07/2025).

A comprehensive medical history was obtained, including assessment of patient complaints, identification of symptoms pathognomonic of somatic diseases, and clarification of the medications taken. This approach facilitated the identification of multiple factors and conditions capable of causing ML of the oral mucosa and lips. When abnormalities in general health status were detected, consultations with appropriate specialists were performed.

The clinical examination included an objective assessment of the oral cavity; evaluation of periodontal tissues with determination of the hygiene index (Greene–Vermillion) and periodontal indices (papillary–marginal–alveolar index, PMA; SPITN); and assessment of the localization, size, and degree of color intensity of ML using a method previously developed by one of the authors (“Methodology for an objective assessment of the degree of melanotic pigmentation,” Certificate for rationalization proposal No. 2869, dated 05/25/1995). The condition of the oral mucosa, periodontium, and lips was examined in an adult cohort of patients who sought consultation or specialized care at the Department of Therapeutic Dentistry of the Myrat Garryev State Medical University of Turkmenistan from 2015 to 2019. Among 1,372 patients examined, ML were identified in 318 cases (23.2%). Patient age ranged from 16 to 39 years, with a mean age of  $34.7 \pm 4.5$  years.

In high-tech dental centers, the degree of melanin pigmentation intensity can be assessed by analyzing digital images using the HSL (Hue, Saturation, Lightness) color model. However, for screening large patient groups and for express assessment of melanin pigmentation saturation, the above-mentioned “Methodology for the objective assessment of the degree of melanin pigmentation” was developed at the Department of Therapeutic Dentistry of the Myrat Garryev State Medical University of Turkmenistan. The essence of the method is as follows: in examined patients, the degree of melanin pigmentation is compared with the intensity of low-saturation dark brown paints No. 61 according to the “Rainbow” mixing catalog developed at the All-Union Scientific Research Institute of Polygraphy (16). According to the ink color scale, pigmentation is divided into seven tones, each corresponding to 14.3% increments based on color intensity. The color intensity of ML was determined by comparison with the corresponding tone of the standard printing inks (Figure 1).

According to the level of saturation, ML were categorized into three degrees:

- Grade I – tone saturation from 14.3% to 28.6%
- Grade II – tone saturation from 42.9% to 57.2%
- Grade III – tone saturation from 71.5% to 100%

The “Rainbow” catalog was originally developed for the printing industry and was widely used in the pre-digital era. References to the use of this catalog in scientific medical literature are lacking; however, in routine domestic healthcare practice, this method has been applied since 1995 for the rapid assessment of ML staining intensity. The principle of dividing the color scale into percentages, which underlies both the “Rainbow” catalog and the method








Tone number	1	2	3	4	5	6	7
Color intensity							
Color intensity, %	14.3%	28.6%	42.9%	57.2%	71.5%	85.8%	100%

Figure 1. Evaluation of the color intensity of ML of the oral mucosa and lips

developed by us, can also serve as a basis for digital image analysis.

**Statistical analysis.** Statistical processing of the clinical trial results was performed using Microsoft Excel and the Statistica software package. The following methods were used to assess the significance of differences: calculation of the mean and standard error, Student's t-test, and analysis of variance, followed by pairwise comparisons to estimate the probability of error (p). Differences between mean values were considered statistically significant at  $P < 0.05$ .

## Results

Of 318 patients aged 16 to 39 years, only 71 (22.3%) presented with complaints related to ML of the oral cavity and lips at the initial consultation. In the remaining 247 cases (77.7%), ML was identified during clinical examination in patients seeking consultation and dental care for other reasons. The anamnestic duration of ML ranged from 12 months to 2 years or longer and was characterized by a gradual increase in color intensity.

Among patients with ML, the skin color in 226 cases (71.1%) corresponded to the Middle Eastern phototype (type IV) according to Fitzpatrick et al. (17), whereas 92 patients (28.9%) corresponded to the European phototype (type III).

Table 1 presents data on the number of patients according to age and localization of ML of the oral mucosa and lips. As shown in the table, ML were most frequently registered in the age group 20–29 years (41.2%), slightly less often in patients aged 30–39 years (33.3%). The lowest number of ML cases was observed in the 16–19-year age group (3.7%). The male-to-female ratio was 9:1 (men,  $n = 286/89.9\%$ ; women,  $n = 32/10.1\%$ ). The predominant localization of ML of the oral cavity and lips was the gingival area (69.2%); lesions occurred five times less frequently on the lips, followed in descending order by the buccal mucosa, tongue, and palate.

At the initial consultation, 81 patients (25.5%) reported bleeding and soreness of the gums during brushing, 174 patients (54.7%) complained of halitosis, and in 53.1% of cases ( $n=169$ ), the reason for visiting a specialist was an

aesthetic defect associated with the presence of ML foci. Patients reported varying disease duration, ranging from 2 months to 2 years or more (mean,  $14.64 \pm 7.25$  months). According to the medical history, 18 patients (5.7%) reported working in open areas.

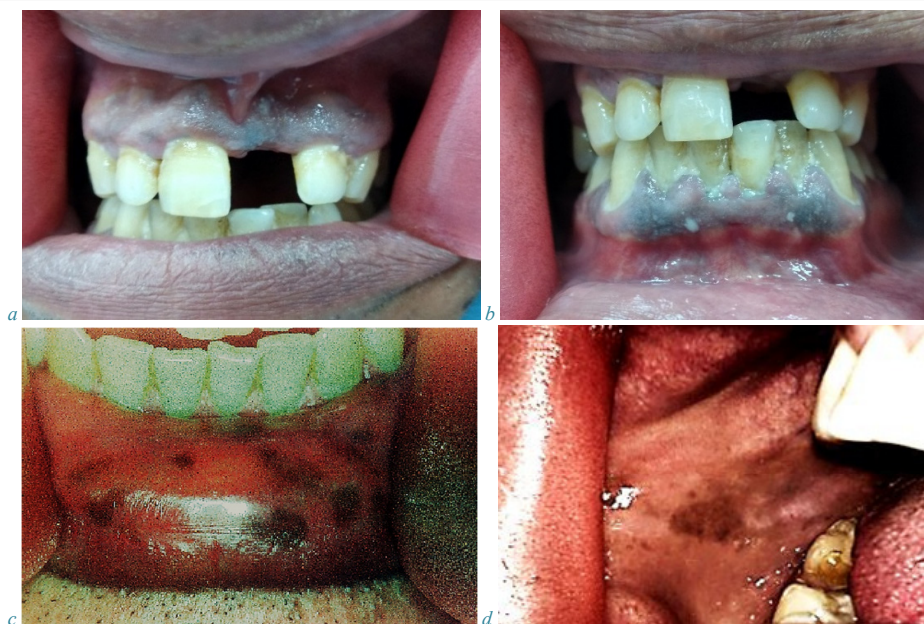On oral examination, a characteristic grayish coating was observed on the surface of the gingival mucosa (Figure 2a, b) in the area of the ML foci. Removal of this coating revealed a dark surface with a pronounced vascular pattern. The surface of the lesions appeared porous and painless. Light-brown spots did not protrude above the level of the mucosa, whereas darker lesions slightly elevated above the mucosal surface. More intense pigmentation was noted in the central part of the foci, with gradual attenuation of color saturation toward the periphery. The borders of the ML were clearly defined with wavy contours, and the shape of the lesions varied (round, oval, ribbon-shaped, irregular). When localized on the buccal mucosa, palate, or lips, the ML foci were flat, showed variable shapes, and had clearly defined margins (Figure 2c); uneven pigmentation could also be observed within the same lesion (Figure 2d).

As a result of the analysis of ML focus size according to anatomical localization (Table 2), small ML foci (1–10 mm) were found predominantly on the labial mucosa (93.2%), palate (66.7%), and tongue (64.3%). Medium-sized ML foci (11–25 mm) were predominantly localized on the buccal mucosa (58.1%) and gingiva (38.2%). ML foci larger than 26 mm were most commonly observed on the gingival mucosa (41.4%), typically involving the interdental papillae with extension to the alveolar part of the gingiva.

Solitary MLs confined to a single anatomical region accounted for 52.8% of cases, including 40.56% localized to the gingival mucosa, 7.86% to the palate, and 2.8% to the buccal mucosa. MLs were observed either as single, localized lesions or as multiple lesions merging with each other and oriented horizontally or vertically. It should be noted that when localized MLs were situated on the buccal and labial mucosa, differential diagnosis of the nature of these lesions was particularly challenging.

Table 1. Summary data on the number of patients according to age and localization of melanotic lesions of the oral cavity and lips.

Age (years)	Gum (n/%)	Cheek (n/%)	Lip (n/%)	Tongue (n/%)	Palate (n/%)	Total patients (n/%)
16-19	9/2.8	2/0.6	1/0.3	-	-	12/3.7
20-29	96/30.2	8/2.5	23/7.2	3/1.0	1/0.3	131/41.2
30-39	77/24.2	9/2.8	11/3.5	7/2.2	2/0.6	106/33.3
40-49	38/12.0	12/3.8	9/2.8	4/1.3	6/1.9	69/21.8
Total	220/69.2	31/9.7	44/13.8	14/4.5	9/2.8	318/100



**Figure 2.** Types of ML on external examination:

a) generalized grade II ML of the alveolar gingiva of the maxilla in a 28-year-old man; a characteristic grayish plaque over the MLs; SPITN index, 2.7; b) the same patient: symmetrical combined generalized grade III ML of the alveolar gingiva of the mandible; c) multiple small grade III MLs of the labial mucosa in a 49-year-old man; and d) grade II ML of the buccal mucosa with a medium-sized lesion in a 37-year-old man.

**Table 2.** Characteristics of ML sizes according to localization.

Anatomical localization of ML	Number of the patients (n)	Length of ML foci		
		Small (1 – 10 mm)	Average (11 – 25 mm)	Extended (26 mm and more)
		n/%	n/%	n/%
Gum	220	45/20.4	84/38.2	91/41.4
Cheek	31	9/29.0	18/58.1	4/12.9
Palate	9	6/66.7	3/33.3	-
Lip	44	41/93.2	3/6.8	-
Tongue	14	9/64.3	5/35.7	-
Total	318	68/21.4	50/36.8	54/39.7

In the remaining 155 cases (48.7%), MLs were multiple or combined (Figure 2a, b), for example, involving the gingival mucosa of both the upper and lower jaws.

Given the predominant localization of ML in the gingival mucosa ( $n = 220/69.2\%$ ), an index-based assessment of periodontal status was performed, on the basis of which a clinical diagnosis was established (Table 3). Comparison of the mean values of the hygiene index, PMA, and CPITN scores demonstrated statistically highly significant differences among the compared nosological forms of inflammatory periodontal diseases ( $P < 0.01$ ). Analysis of the results revealed a significant predominance of generalized forms of chronic inflammatory periodontal diseases ( $P < 0.05$ ), namely chronic generalized catarrhal gingivitis in 27.7% of cases and chronic generalized periodontitis of moderate severity in 38.2% of cases.

At the same time, when ML was localized on the mucous membranes of the cheek, lip, tongue, and palate ( $n = 98$ ), all cases also exhibited clinical signs of chronic inflammatory periodontal diseases, including chronic localized catarrhal gingivitis in 7 patients (7.1%), chronic generalized catarrhal gingivitis in 25 patients (25.5%), chronic localized periodontitis of moderate severity in 18 patients

(18.4%), and chronic generalized periodontitis of moderate severity in 48 patients (49.0%).

After establishing a clinical diagnosis in accordance with our developed method for assessing the degree of ML, a comparative analysis of ML staining intensity was performed in relation to the nosological form of inflammatory periodontal diseases and the size of the ML foci; the results are presented in Table 4. The analysis showed that the size of the ML foci increased significantly with the depth and extent of the inflammatory process in the periodontium. Comparative analysis of the mean length of the ML foci according to disease form demonstrated statistically significant differences among all compared nosological forms ( $P < 0.01$ ). Pairwise comparison of the mean width of ML foci of the periodontal mucosa according to disease form also revealed statistically significant differences ( $P < 0.05$ ).

A similar relationship was observed when comparing the intensity of periodontal mucosal staining with the nosological form of inflammatory periodontal diseases. According to the method we developed for the objective assessment of staining intensity of the periodontal mucosa of the oral cavity and lips, patients were distributed as follows: grade I, 82 patients (25.8%); grade II, 164 patients (51.6%); and grade

Table 3. Index assessment of oral hygiene and periodontal tissue condition in patients with ML of the gingiva

Clinical diagnosis	Number of the patients (n%)	Hygienic index	PMA %	CPITN				
				Healthy sextant	Bleeding	Dental calculus	Periodontal pocket	Unaccounted sextants
				M±m				
Chronic localized catarrhal gingivitis	39/17.7	1.9±0.04*	22.2±1.8*	4.1±0.1*	1.4±0.1	0.5±0.1*	-	-
Chronic generalized catarrhal gingivitis	61/27.7	2.3±0.08	33.4±0.7*	3.0±0.1	1.9±0.1*	1.1±0.1	-	-
Chronic localized periodontitis of moderate degree	36/16.4	2.4±0.06	51.1±1.3*	2.5±0.1*	1.2±0.1*	1.2±0.1*	1.1±0.1*	-
Chronic generalized periodontitis of moderate degree	84/38.2	2.8±0.04*	60.3±0.4*	0.9±0.1*	1.6±0.1	1.7±0.1*	1.8±0.1	-
Total	220	-	-	-	-	-	-	-

Note: \*  $P < 0.01$ 

Table 4. The degree of intensity of MP staining depending on the nosological forms of inflammatory periodontal diseases and the size of the lesions

№	Nosological form of periodontal diseases	Number of the patients n/%	Size of foci of melanotic lesions (M±m)		Degree of intensity of coloration of ML		
			Length (mm)	Width (mm)	I	II	III
1	Chronic localized catarrhal gingivitis	46/14.5	3.9±0.3	4.1±0.3	37	9	-
2	Chronic generalized catarrhal gingivitis	86/27.0	5.0±0.3	3.1±0.2	45	28	13
3	Chronic localized periodontitis of moderate degree	54/17.0	13.3±0.9	5.05±0.2	-	36	18
4	Chronic generalized periodontitis of moderate degree	132/41.5	27.7±1.6	5.5±0.1	-	91	41
	Total	318/100	-	-	82	164	72

Table 5. Principles of clinical classification of melanotic lesions of orolabial localization

I) By anatomical localization of melanotic lesions			
One anatomical area:		Combined (2 and more anatomical areas):	
-	MM of the gum: of the upper jaw, of the lower jaw;	-	MM of both jaws;
-	Unilateral MM of the cheek;	-	MM of both lips;
-	MM of the tongue: medially, laterally, tip of the tongue;	-	Combination of different anatomical areas.
-	MM or red border of the lips: upper, lower	-	Symmetrical arrangement;
		-	Asymmetrical arrangement
II) By the degree of the extent and sizes of melanotic lesions			
Localized form:		Generalized form:	
-	small (1-10 mm);	extended 26 mm and more.	
-	average (11-25 mm)		
III) By the degree of color intensity			
(based on comparison with the intensity of low-saturated colors of dark brown tone N 61 according to the mixing catalog "Raduga")			
Degree I:	Degree II:	Degree III:	
light brown color.	brown color.	dark brown color.	

III, 72 patients (22.6%).

Statistically significant differences in grade I ML were identified between nosological forms first and second of inflammatory periodontal diseases ( $P < 0.05$ ). Analysis of grade II ML revealed significant differences between nosological forms first and second, first and third, first and fourth, second and third, and second and fourth ( $P < 0.05$ ), whereas no differences were observed between forms third and fourth ( $P > 0.05$ ). Comparison of grade III ML also demonstrated highly significant differences between nosological forms second and third, and between forms second and fourth ( $P < 0.01$ ). No statistically significant differences were found between forms third and fourth of inflammatory periodontal diseases for grade III ML ( $P > 0.05$ ).

All patients who sought treatment for inflammatory periodontal diseases underwent comprehensive therapy. Follow-up oral examinations performed 2.5-6 months later in 82 patients (25.8%) revealed changes in color intensity,

characterized by a decrease in pigmentation saturation to a lower grade and a reduction in the number and/or size of lesions localized in the gingival mucosa.

Based on the above diagnostic criteria and our findings, we developed a clinical classification to objectively formulate the clinical diagnosis of "ML of the oral mucosa and lips" (Table 5).

## Discussion

The results of this retrospective study enabled the development of a clinical classification of ML of the oral mucosa and lips, the occurrence of which is not associated with racial pigmentation, somatic diseases, or exogenous factors. On the basis of this classification, principles for formulating a clinical diagnosis were proposed, allowing not only a comprehensive and objective description of the clinical presentation but also facilitating the differential diagnosis of ML.

Using the criteria defining the concepts of “localized” and “generalized” gingivitis or periodontitis in the Classification of Inflammatory Periodontal Diseases, we attempted to classify ML foci of the orolabial mucosa according to the size of the pigmented area, as follows:

- ML in the form of small pigmented foci measuring 1–10 mm, localized predominantly on the vermilion border and labial mucosa, as well as in the interdental mucosa;
- Medium-sized ML (11–25 mm), most commonly located on the mucosa of the interdental papillae with extension into the interdental spaces or the alveolar gingiva of both jaws, and less frequently on the buccal mucosa;
- Melanosis in the form of extended lesions (26 mm or more), presenting as ribbon-shaped or wavy bands, detected exclusively on the mucosa of the alveolar gingiva.

Thus, the characteristic clinical signs of ML of the orolabial mucosa include:

- Absence of somatic diseases, including systemic, hereditary, and endocrine disorders;
- Use of medications that promote mucosal pigmentation and other exogenous influences;
- Frequent complaints of gingival bleeding and soreness during tooth brushing, halitosis, and aesthetic concerns related to the appearance of ML;
- Disease duration: ranging from 2 weeks to 2 years or longer;
- The highest incidence among individuals aged 20–39 years, with a marked male predominance of 9:1;
- In cases of gingival localization of ML, the consistent presence of chronic inflammatory periodontal diseases, with a direct correlation between the clinical characteristics of ML and the nosological forms of periodontal disease;
- Presence of a characteristic grayish plaque on the gingival mucosa in the area of ML foci, which, upon removal, reveals a dark, porous, painless surface with a pronounced vascular pattern during oral examination;
- Light brown lesions (grade I color intensity) generally not protruding above the mucosal surface, whereas darker lesions (grades II-III) slightly elevated above the mucosa;
- Maximal color intensity in the center of the lesions with gradual attenuation toward the periphery in extended (26 mm or more) and medium-sized (11–25 mm) localized periodontal lesions;
- Clearly defined borders, often wavy or jagged, with variable lesion shapes (round, oval, ribbon-shaped, or irregular);
- predominance of extended (generalized) ribbon-shaped or wavy lesions and medium-sized lesions localized to the gingival mucosa, mainly involving the marginal and alveolar gingiva;
- frequent involvement of two or more anatomical regions (combined lesions);
- symmetrical distribution of lesions on the marginal and alveolar gingiva in patients with chronic generalized inflammatory periodontal diseases.

The feasibility of this methodological approach to a comprehensive and objective formulation of the clinical diagnosis also allows the clinician to select the optimal treatment strategy. For example, a transition from stage I periodontal ML to stage II periodontal ML after a course of

treatment for inflammatory periodontal diseases indicates progression of the periodontal pathology, which, in turn, triggers melanosis. Conversely, a change from stage III periodontal ML to stage II or I, accompanied by a reduction in the size of ML foci, indicates treatment effectiveness. This conclusion is supported by the statistical data obtained in the present study, demonstrating that with increasing depth and generalization of chronic inflammatory periodontal diseases, both the size and intensity of periodontal ML increase. Supplementing the clinical classification of periodontal ML with the proposed objective criteria eliminates subjective interpretation of the process, for example, in situations such as patient relocation.

In our view, one of the key principles in formulating a clinical diagnosis is the precise specification not only of the anatomical location and size of ML, but also of the nature of the lesions, namely whether they are solitary or combined, involving two or more anatomical regions, and whether their distribution is symmetrical or asymmetrical.

For the assessment of treatment effectiveness or during dynamic follow-up, the clinical diagnosis should be supplemented with information on the extent and size of ML: localized (small or medium-sized lesions) or generalized forms.

A third fundamental principle in formulating a clinical diagnosis is the specification of the degree of ML color intensity. This objectification of the diagnosis eliminates subjective assessment of pigmentation saturation and may also serve as a criterion for differential diagnosis or for evaluating treatment efficacy. Thus, the final clinical diagnosis of ML of the oral mucosa and lips should be formulated, for example, as “generalized ML of the alveolar gingiva, grade II, projecting to teeth 11, 12, and 13” or “multiple small grade III ML of the lower lip.”

The data obtained in this study cannot be directly compared with the findings of other researchers, as the vast majority of published studies focus primarily on the etiopathogenetic aspects of ML of the oral mucosa, describing the clinical presentation of the lesions themselves as well as their pathomorphological features (2, 3, 6-8, 11, 12, 15, 18-20). An analysis of the scientific literature over the past decade revealed no studies reporting oral hygiene levels and periodontal status with index-based assessment in patients of this category.

### Conclusion

The proposed fundamental approaches to formulating a clinical diagnosis of orolabial ML provide objective criteria for differential diagnosis in cases where verification of lesion nature is challenging, as well as for assessing disease dynamics and treatment effectiveness. Evaluation of ML staining intensity using digital image processing or the method developed by the authors represents an important diagnostic indicator; moreover, the simplicity of this approach allows its application for rapid diagnostics during screening. The proposed classification and principles for formulating a clinical diagnosis of orolabial ML may also be used to systematize and objectify the diagnosis of non-melanocytic pigmentation of the oral cavity and lips.

**Acknowledgment**

N/A.

**Conflict of Interests**

The authors declare that they have no competing interests.

**Authors' Contributions**

H.J.: overall coordination, conceptualization, methodology, supervision, data analysis and interpretation, manuscript editing, and final approval.

A.T.: data analysis at all stages of manuscript preparation, including drafting and critical revision, and ensuring compliance with ethical standards for conducting research.

B.S.: literature review, data collection, and statistical analysis.

G.G.: interpretation of clinical results, participation in discussions regarding treatment implications, and preparation of figures and tables.

B.A.: participation in patient data collection and ensuring the accuracy of clinical data presentation.

A.G.: expertise in health information management, assistance with results interpretation, and manuscript formatting.

**Ethical Considerations**

Ethics Committee approval of the Myrat Garryev State Medical University of Turkmenistan No. 1665, dated 10/07/2025.

**Funding Support**

N/A.

**Data Availability**

All data generated or analyzed during this study are included in this published article.

**AI Use Statement**

The authors confirm that no Artificial Intelligence (AI) or AI-assisted technologies were used in the writing of this manuscript or the data analysis process.

**References**

- Thomson P. Oral pigmented lesions: a pragmatic approach to diagnosis and management. *Fac Dent J.* 2024;15(3):90-96. doi:10.1308/rcsfj.2024.30
- Rosebush MS, Briody AN, Cordell KG. Black and Brown: Non-neoplastic Pigmentation of the Oral Mucosa. *Head and Neck Pathology.* 2019 Jan 22;13(1):47-55. <https://doi.org/10.1007/s12105-018-0980-9>
- Müller S. Melanin-associated pigmented lesions of the oral mucosa: presentation, differential diagnosis, and treatment. *Dermatol Ther.* 2010 May-Jun;23(3):220-9. doi: 10.1111/j.1529-8019.2010.01319.x
- Ko E, Panchal N. Pigmented Lesions. *Dermatol. Clin.* 2020 Oct;38(4):485-494. doi: 10.1016/j.det.2020.05.009
- Tavares TS, Meirelles DP, de Aguiar MCF, Caldeira PC. Pigmented lesions of the oral mucosa: A cross-sectional study of 458 histopathological specimens. *Oral Dis.* 2018 Jul 10;24(8):1484-1491. doi: 10.1111/odi.12924
- Alawi F. Pigmented lesions of the oral cavity: An Update. *Dent Clin North Am.* Author manuscript. 2013 Aug 15;57(4):699-710. doi: 10.1016/j.eden.2013.07.006

- Kauzman A, Pavone M, Blanas N, Bradley G. Pigmented Lesions of the Oral Cavity: Review, Differential Diagnosis, and Case Presentations. *J Can Dent Assoc.* 2004 Nov;70(10):682-3. PMID: 15530266. Pub Med
- Belysheva TS, Vishnevskaya YaV, Kletskeya IS, Michenko AV, Volkova AS, Valiev TT, et al. Problems of clinical and morphologic diagnosis of orolabial melanosis in children. *Russian Journal of Pediatric Hematology and Oncology.* 2021;8(3):116-122. (In Russ.)
- Sreeja C, Ramakrishnan K, Vijayalakshmi D, Devi M, Aesha I, Vijayabanu B. Oral pigmentation: a review. *J Pharm Bioallied Sci.* 2015 Aug;7(Suppl 2):S403-8. doi: 10.4103/0975-7406.163471
- Nikitakis NG, Koumaki D. Laugier-Hunziker syndrome: case report and review of the literature. *Oral Surg Oral Med Oral Pathol Oral Radiol.* 2013 Apr 2;116(1):e52-8. doi: 10.1016/j.oooo.2012.12.012
- Gondak RO, da Silva-Jorge R, Jorge J, Lopes MA, Vargas PA. Oral pigmented lesions: clinicopathologic features and review of the literature. *Med Oral Patol Oral Cir Bucal.* 2012 Nov 1;17(6):e919-24. doi: 10.4317/medoral.17679
- Lambertini M, Patrizi A, Ravaioli GM, Dika E. Oral pigmentation in physiologic conditions, post-inflammatory affections and systemic diseases. *G Ital Dermatol Venereol.* 2017 Apr 19;153(5):666-671. doi: 10.23736/S0392-0488.17.05619-X
- Abati S, Sandri GF, Finotello L, Polizzi E. Differential Diagnosis of Pigmented Lesions in the Oral Mucosa: A Clinical Based Overview and Narrative Review. *Cancers (Basel).* 2024 Jul 8;16(13):2487. doi: 10.3390/cancers16132487
- Fritz A, Percy C, Jack A, Shanmugaratnam K, Sobin L, Parkin DM, et al. The International classification of diseases for oncology (ICD-O), 3rd edition, 1st revision, 242 pages. WHO, 2013. ISBN 978 92 4 154849 6 (NLM classification: QZ 15). ISBN 978 92 4 069212 1 (PDF)
- Cantudo-Sanagustin E, Gutierrez-Corrales A, Vigo-Martinez M, Serrera-Figallo MA, Torres-Lagares D, Gutierrez-Perez JL. Pathogenesis and clinicohistopathological characteristics of melanoacanthoma: a systematic review. *J Clin Exp Dent.* 2016 Jul 1;8(3):e327-36. doi: 10.4317/jced.52860
- Fajnberg IS, Sulzhenko NP, Davidov IE. Catalogue light saturated colours. Eight-colorful system of displacement "Rainbow". Moscow: All-Union Scientific Research Institute of Polygraphies. 1985; 5(2):56 ill. p.
- Garcia GC, Khan MN, Alam A, Obregon J, Abuhmed T, Huh E-N. FiSC: A Novel Approach for Fitzpatrick Scale-Based Skin Analyzer's Image Classification. *IEEE Access.* 2025(March); Vol.13: 42934-42948. DOI: 10.1109/ACCESS.2025.3547573
- Mallikarjuna K, Gupta S, Shukla S, Chaurasia S. Unusual extensive physiologic melanin pigmentation of the oral cavity: a clinical presentation. *J Indian Soc Pedod Prev Dent.* 2013 Apr-Jun;31(2):121-5. doi: 10.4103/0970-4388.115718
- Ferreira L, Jham B, Assi R, Readinger A, Kessler HP. Oral melanocytic nevi: a clinicopathologic study of 100 cases. *Oral Surg Oral Med Oral Pathol Oral Radiol.* 2015 May 28;120(3):358-67. doi: 10.1016/j.oooo.2015.05.008
- Ison J, Clark A. Pigmented Lesions of the Oral Cavity. *Oral Maxillofac. Surg. Clin. N. Am.* 2023 May;35(2):153-158. doi: 10.1016/j.coms.2022.10.008